

# COMPREHENSIVE UTILIZATION OF BUR AND ROTARY INSTRUMENTATION FOR THE PREPARATION AND FINISHING OF FULL-COVERAGE CROWN RESTORATIONS

Michael C. Fling, DDS • Jeff Singler, CDT

*In order to achieve exceptional oral rehabilitation, a dentist and laboratory technician must integrate the technical and artistic skills of both professionals. Clinicians, technicians, and patients have respective interpretations of appropriate color, contour, texture, and dimension for restorations. A team approach, requiring sound communication, establishes a treatment plan that prevents oversights and conveys critical information efficiently and effectively. Since technical skill and clear clinical expectations are vital to success, this article outlines the preparation guidelines for a porcelain-fused-to-metal restoration and highlights effective communication techniques between the clinician and technician to achieve optimal restorative results and patient satisfaction. Further, the "Shadow Preparation" technique is presented, as well as the fabrication of the restorations to be placed.*

An increasing number of patients that present today are requesting aesthetic and durable restorations. It is therefore incumbent upon the clinician and technician to communicate information regarding the appropriate space and contours required for an enhanced aesthetic result. With clinical photography, a detailed prescription, and a diagnostic waxup, the clinician and technician are able to successfully communicate the goals, expectations, and limitations for each restorative case. Utilizing the


diagnostic waxup, treatment alternatives and technical alterations can be considered. The diagnostic waxup can then serve as a postoperative model, offering a physical image of the definitive result.

## CLINICAL SEQUENCE

Utilization of the porcelain shoulder crown restoration is common in dentistry today. In most circumstances, porcelain-fused-to-metal (PFM) restorations provide an aesthetic, functional, and durable result, demonstrating enhanced predictability. A preparation technique that



*Dr. Fling maintains a private practice in Oklahoma City, OK, with an emphasis in Restorative Dentistry. He is a Clinical Assistant Professor in the Department of Fixed Prosthodontics at the Oklahoma University College of Dentistry, Oklahoma City, OK. Dr. Fling lectures nationally and is a member of the American Academy of Restorative Dentistry and the American Academy of Fixed Prosthodontics.*



*Mr. Singler is a certified dental technician and the founder of Singler Dental Ceramics, Inc. in Dallas, TX, focusing on complex restorative cases and implant restorations. He lectures nationally on topics such as implant dentistry and ceramics.*

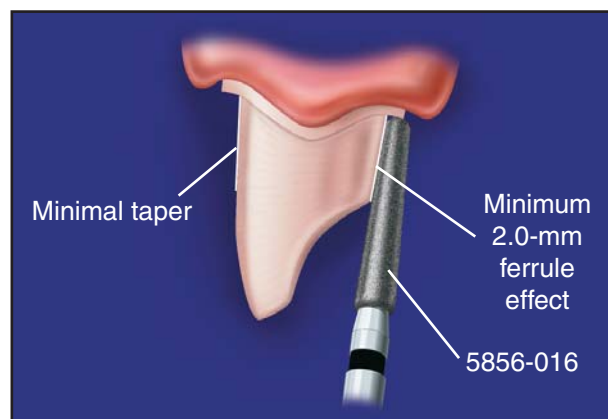


Figure 1. A 2.0-mm circumferential shoulder provides opposing axial walls, creating an adequate ferrule effect.

respects the physiology of the soft tissue by reminding the clinician of the importance of following the free gingival margin (FGM) as well as respecting the physiology of the hard tissue, while facilitating adequate contours and space for restoration fabrication, should be a primary concern of the dentist and laboratory technician. The fundamental considerations for this preparation technique follow:

### 1. Periodontal Health/Crest Type Identification—

Tissue appearance, FGM height, probing depths, amount of keratinized tissue, and the crown-to-root ratio must be evaluated preoperatively. Since aesthetic restorations typically present with margins at or below the FGM, biologic width infringement may result in inflammation, recession, or loss of attachment.<sup>1</sup> Kois suggests a “crest type” be identified by measuring from the FGM to the alveolar crest,<sup>2</sup> providing the clinician with a level of predictability for tissue response preoperatively.

**2. Retention/Resistance—**Resistance can be greatly enhanced by increasing the prepared surface area.

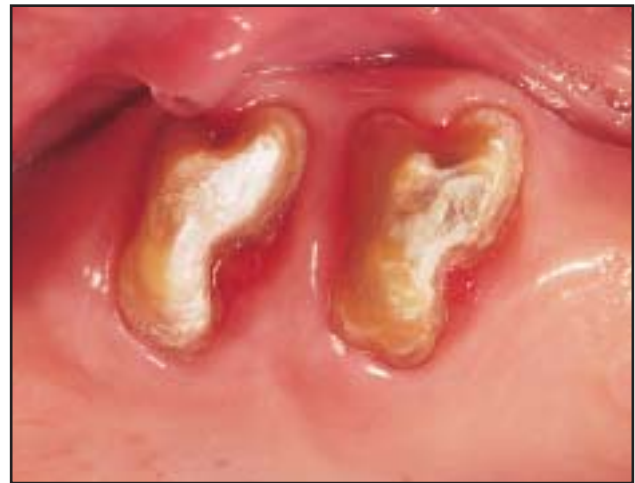Shillingburg suggests a 6° taper of the axial walls as ideal<sup>3</sup> (5856-014, Brasseler USA, Savannah, GA).

However, later studies by Kent et al suggest the use of a minimal taper.<sup>4</sup> Creating opposing axial walls with a circumferential shoulder “shadowing” the contours of the tooth perimeter facilitates an adequate ferrule effect, which should be a minimum of 2.0 mm.<sup>5,6</sup> While retention and resistance are increased, this also enables adequate space for a proper emergence profile and an aesthetic porcelain shoulder (Figure 1).

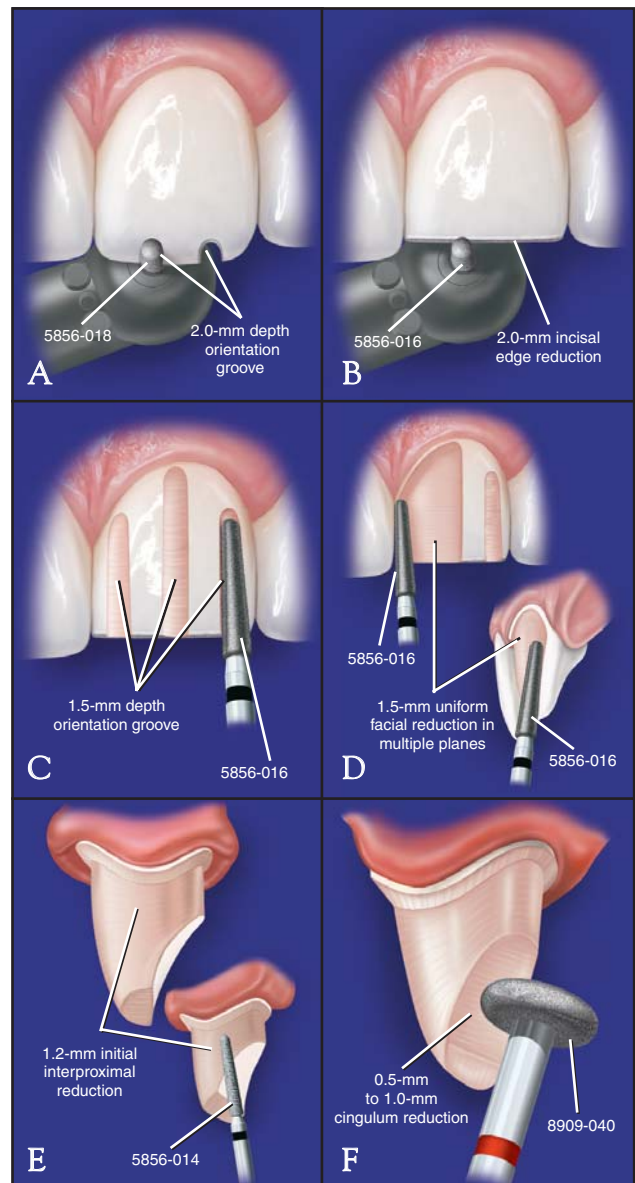
**3. Adequate Tooth Reduction—**The clinician and technician must agree on the degree of reduction necessary to maintain the integrity of the hard and soft tissue.

Although the prepared tooth may be vital and present without symptoms, there is a 5.7% risk of pulpal involvement following tooth reduction.<sup>7</sup> A reduction of 2.0 mm is necessary for the incisal edge and 1.5 mm for shoulder and facial reduction.

**4. Margin Type/Placement—**Most aesthetic restorations require margin placement at or below the FGM. However, cervical limitations must be considered.<sup>8</sup> Kois suggests that a “normal crest” sounding depth—a measurement of 3.0 mm from the FGM to the alveolar crest—indicates stable tissue, enabling margins to be



**Figure 2.** A circumferential shoulder “shadows” the exterior perimeter of the posterior dentition.

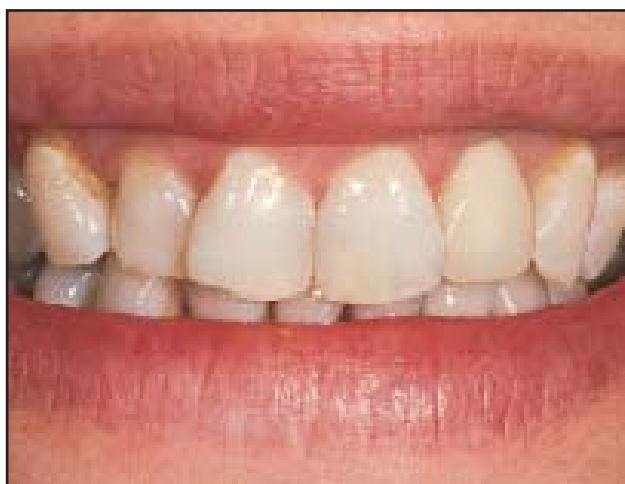

**Figure 3.** Illustrated view of the “Shadow Preparation” technique.

### SHADOW PREPARATION GUIDELINES

Incisal edge reduction	2.0 mm
Facial depth orientation grooves	1.5 mm
Facial reduction	1.5 mm
Initial interproximal reduction	1.2 mm
Final interproximal reduction	1.5 mm
Lingual axial reduction	1.0 mm
Cingulum reduction	0.7 mm to 1.0 mm
Shoulder refinement	1.5 mm
Bevel placement	0.5 mm

**Table.** The “Shadow Preparation” technique requires a complete reduction of the entire tooth.



**Figure 4.** Pretreatment observations include surface texture and glaze, internal and external translucencies, dislocation, fracture lines, and wear patterns.

placed 0.5 mm to 1.0 mm subgingivally.<sup>2</sup> A “low crest” sounding depth—a measurement of greater than 3.0 mm—indicates unstable tissue, requiring margin placement at or above the FGM, which may compromise aesthetics. When margins are placed subgingivally in a “low crest” preparation, provisionalization and tissue evaluation for resultant recession are necessary prior to fabrication of the definitive restoration. A “high crest” sounding depth—a measurement of less than 3.0 mm—indicates a short dentogingival complex, in which subgingival margins may result in biologic width infringement.

Pascoe concluded that beveled margins reduce marginal openings but do not facilitate complete seating of the casting.<sup>9</sup> Rosner popularized the “sliding joint,” suggesting that the closer the angle of a bevel to the axial surface, the greater the marginal closure.<sup>10</sup> Ostlund demonstrated, however, that when a specific film thickness of cement is introduced, marginal closure is inhibited when a bevel is angled to approximate the axial surface.<sup>11</sup> He concluded that the greatest marginal closure will occur when utilizing a 90° shoulder for a conventionally cemented restoration.

Metal margins facilitate verification of proper crown seating and are less technically demanding than the 360° porcelain shoulder. If a metal lingual band is utilized with a 360° shoulder preparation, but without a lingual bevel, extreme care must be taken during polishing, since any vertical reduction of the metal will result in

### BRASSLER ARMAMENTARIUM REQUIRED

#### Diamonds



5856-014  
A round-end tapered diamond



5856-016  
A round-end tapered diamond



5856-018  
A round-end tapered diamond



8909-040  
A round-wheel diamond



10839-012  
A flat end-cutting diamond



848-016  
A flat-end tapered diamond



842-018  
A flat-end cylindrical diamond

#### Carbides



H379-014  
A football-shaped carbide bur



H246-009  
A flame-shaped carbide bur



H73EF-023  
A bullet-shaped carbide cutter



H129DF-023  
A rounded-end carbide cutter



H138EF-023  
A rounded-end tapered carbide cutter



H547-040  
A dowel pin access bur



0053-031  
A fine-grit prepolishing point

#### Polisher

an open margin. Utilizing a bevel, loose enamel rods are removed and the process of polishing the metal band does not significantly threaten marginal integrity. Therefore, when placing a bevel, a carbide bur with a more concave finish angle should be considered to reduce the acute angle of the bevel.

### “Shadow Preparation” Technique

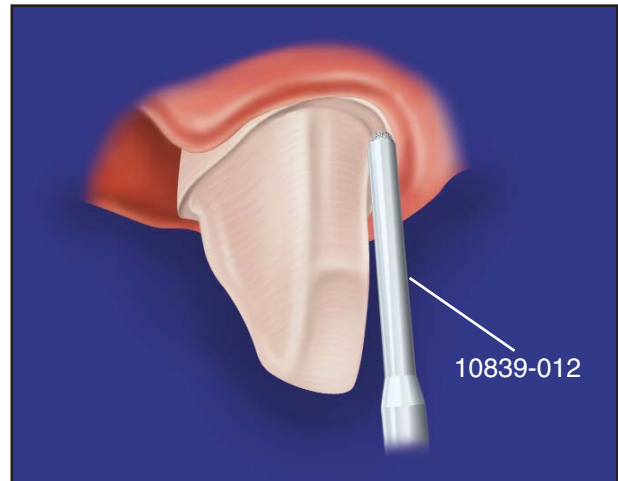
The “Shadow Preparation” technique is a shoulder preparation that follows or “shadows” the exterior of the tooth perimeter and is utilized for anterior and posterior dentition (Figure 2). The procedure facilitates more parallel axial walls, provides optimum ferrule effect, and ensures adequate space for the emergence profile and enhanced aesthetics<sup>5,6</sup> (Figure 3) (Table).

### CASE 1

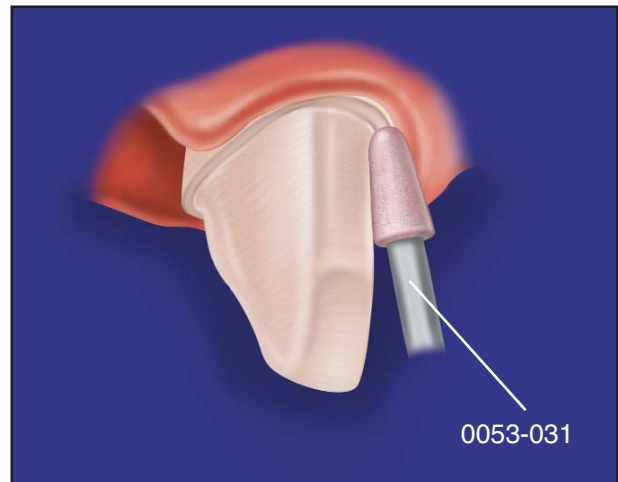
A 38-year-old female patient presented requesting restoration of unaesthetic anterior dentition (Figure 4). Discoloration, surface texture and glaze, internal and external translucencies, wear patterns, and fracture lines were examined prior to prescribing full-coverage crown restorations for teeth #6 through #11 in order to provide enhanced strength and a natural-looking result. Utilizing the diagnostic waxup as a guide, the “Shadow Preparation” technique was utilized to prepare the teeth, facilitating easier placement during cementation protocol.

**Incisal Reduction**—Utilizing a round-end tapered diamond (5856-018, Brasseler USA, Savannah, GA), 2.0-mm depth orientation grooves were created, beginning at the desired incisal edge position. Reduction of the entire incisal edge was then accomplished. Overreduction of the preparation may result in porcelain restorations that are too thick and unsupported, contributing to porcelain fractures or pulpal infringement. Loss of translucency or opacity may result from underreduction.

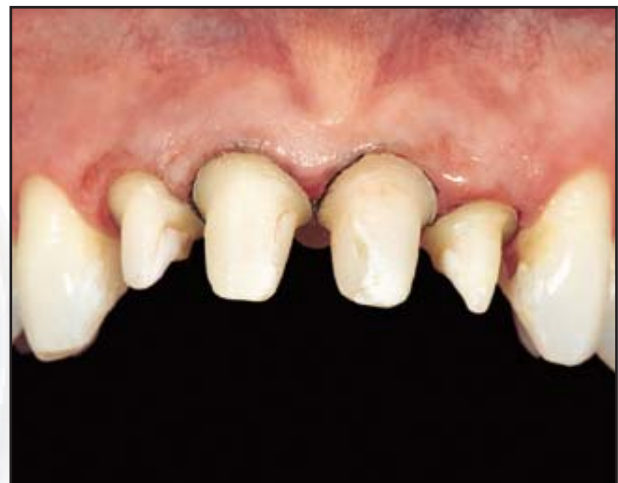**Facial Reduction**—Utilizing a round-end tapered diamond (5856-016, Brasseler USA, Savannah, GA), three 1.5-mm depth orientation grooves were placed at the midfacial, mesial facial, and distal facial line angles. Following the scallop of the FGM, the reduction was completed by connecting the midfacial



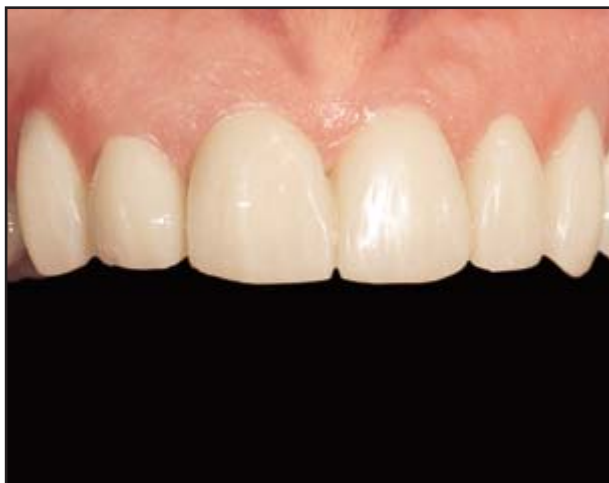**Figure 5.** A flat end-cutting diamond eliminates the remaining lip of the tooth structure and any loose enamel rods.



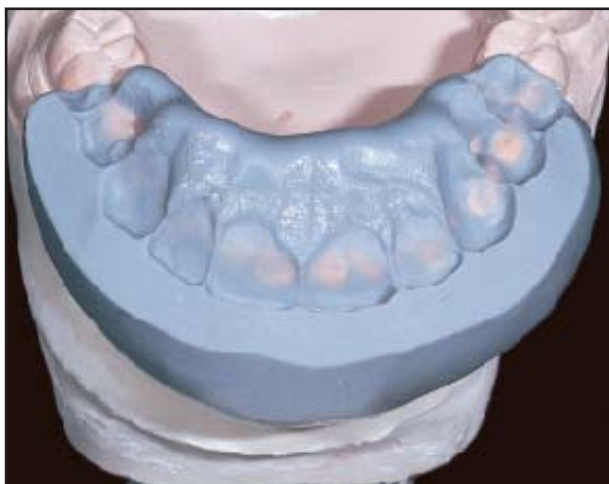**Figure 6.** A fine-grit prepolishing point is utilized to thin the margin and exhibiting light pressure, the shoulder is polished.



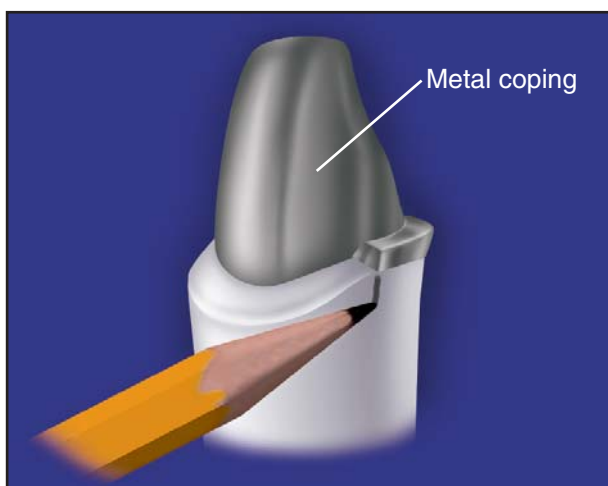
**Figure 7.** The “Shadow Preparation” technique provides optimum ferrule effect, more parallel axial walls, and adequate space for the emergence profile and enhanced aesthetics.



**Figure 8.** Image of the provisional restorations demonstrating the restorative goals of the patient and clinician.



**Figure 9.** The mounted cast registers lingual, occlusal, and incisal anatomy.



**Figure 10.** The metal band ends at a 90° finish, eliminating the common “fade out” of metal, resulting in an opaque appearance.

depth orientation groove with the lateral depth orientation grooves located at, or incisally to, the interdental papilla. By preserving the interproximal papilla and not severing these transeptal fibers, the risk of recession was significantly reduced. The facial reduction was completed by “blending” the reduced area from the gingival shoulder to the incisal edge in multiple planes.

#### **Interproximal and Lingual Axial Reduction—**

A round-end tapered diamond (5856-014) was utilized to break the interproximal contact and minimize the likelihood of interproximal overreduction. Shoulder reduction continued through the interproximal area and across the lingual, following the FGM. This 360° shoulder “shadowed” the exterior tooth perimeter, creating opposing, parallel axial walls. The lingual shoulder was narrowed to 1.0 mm, which still allowed space for the laboratory technician to fabricate a proper emergence profile while maintaining the structural integrity of the preparation. A round-end tapered diamond (5856-018) was then utilized to slightly widen the interproximal shoulder after breaking the interproximal contacts.

#### **Cingulum Reduction—**

Cingulum reduction was completed utilizing a round-wheel diamond (8909-040, Brasseler USA, Savannah, GA). If a metal lingual surface was to be treatment planned, a minimum of 0.7-mm clearance would have been required. However, 1.0-mm clearance would be the minimum if the lingual aspect was to be porcelain.

#### **Refinement—**

A flat end-cutting diamond (10839-012, Brasseler USA, Savannah, GA) was utilized to eliminate any overhang or loose enamel rods (Figure 5). By exerting light pressure, a fine-grit, prepolishing point (0053-031, Brasseler USA, Savannah, GA) was utilized to polish the shoulder (Figure 6). Since a round-end tapered diamond was utilized for axial reduction, the junction of the shoulder-to-prepared-axial surface was rounded, relieving fatigue or stress in the prepared tooth.<sup>12</sup> Finally, all internal line angles were slightly rounded and smoothed (Figure 7). Utilizing a carbide bur (H379-014, Brasseler USA, Savannah, GA), a bevel was placed lingual to the aesthetic zone, where the metal band was to be present. Due to limited

space, a thinner carbide bur (H246-009, Brasseler USA, Savannah, GA) was necessary within the interproximal area.

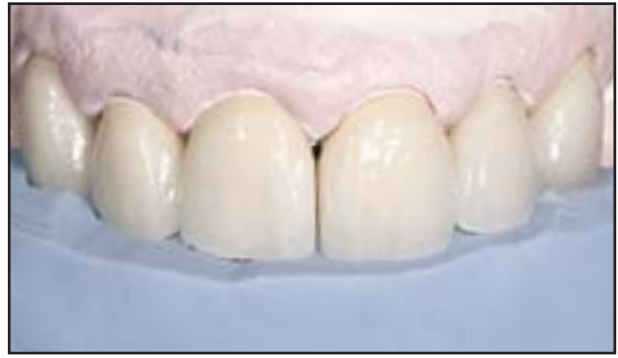### LABORATORY COMMUNICATION

After completing the clinical phase of treatment, it was imperative that the clinician provide the laboratory technician with specific physical communication components such as clinical slides, mounted casts, written prescriptions, and recorded notations, ensuring that the desired levels of function and aesthetics were achieved.

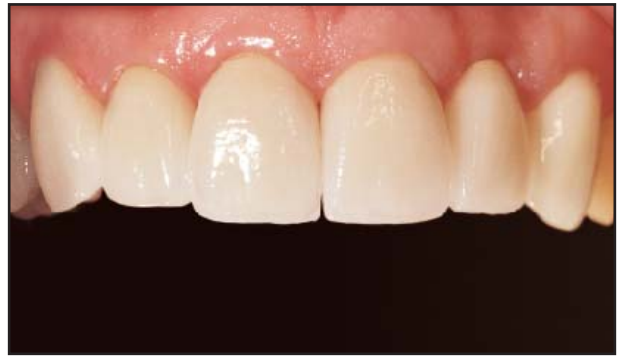**Clinical Slides**—Preoperative 35-mm slides were useful in evaluating surface texture and glaze, internal and external translucencies and anomalies, fracture lines, wear patterns, shapes and contours, decalcifications, and natural tooth color compared to various shade tabs. Additionally, the slides enabled the technician to evaluate dentin color, facilitating proper selection of opaque modifiers. Images of the refined provisional restorations were also useful, since the precisely contoured provisional restorations demonstrated the restorative goal of the clinician (Figure 8).

**Mounted Casts**—Mounted preoperative study casts enabled the laboratory technician to evaluate several important characteristics of the patient's dentition, including tooth shape, contour, texture, and occlusion. A mounted cast of the provisional restorations was submitted to provide the technician with a physical model of the anticipated, completed case. Since the provisional restorations were refined to match the anticipated results, silicone indices were utilized to facilitate the fabrication process, as follows.

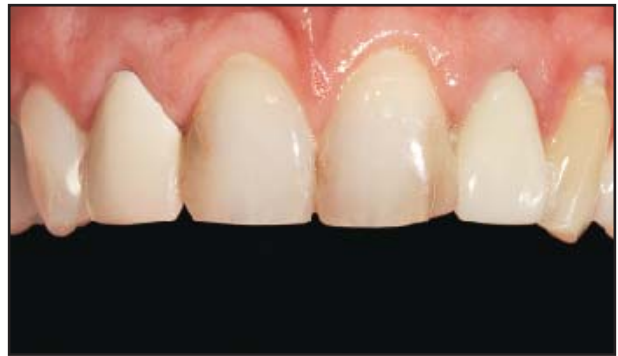1. **Facial Index:** Verified the facial axial contour and position. This was required to facilitate framework design and ensure proper support with optimum space (1.5 mm minimum, 0.3 mm for the framework; 1.2 mm for the porcelain) for porcelain addition.
2. **Incisal Index:** Verified the incisal edge length and position. This was critical, since it directly affected aesthetics, function, and phonetics.
3. **Interocclusal Index:** Once the provisional cast was mounted, it was placed in centric occlusion with a silicone index material interposed. Lingual, occlusal, and incisal anatomy were registered (Figure 9). Following removal of the provisional cast, the working cast was



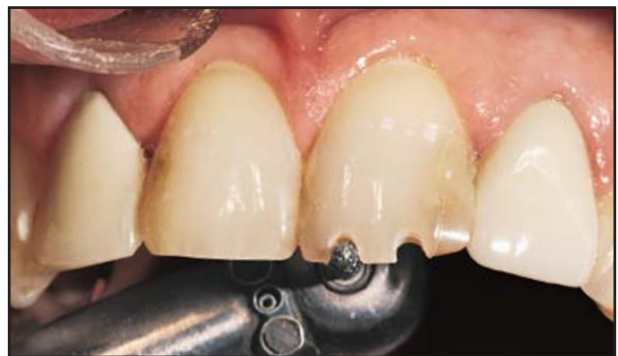**Figure 11.** The final restorations are created to precisely match the indices, mimicking the contours of the provisionals.



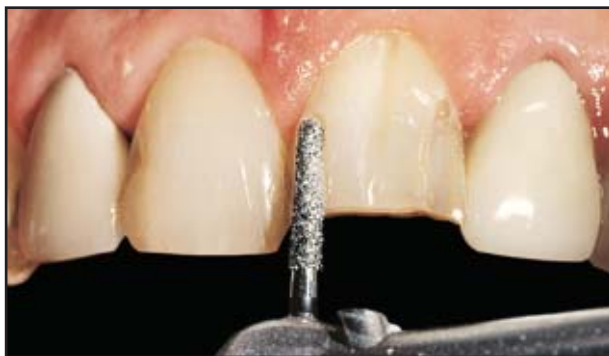**Figure 12.** Facial view of the final restorations. Note the improved aesthetics demonstrated by the restorations.



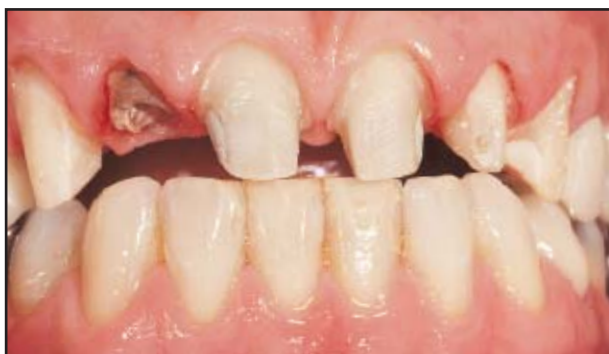**Figure 13.** Preoperative view of the dentition demonstrating unaesthetic crowns.



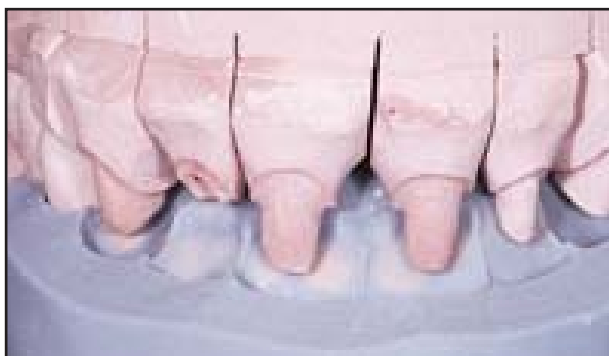**Figure 14.** Following the fabrication of a diagnostic waxup, the "Shadow Preparation" technique was utilized to prepare the dentition.



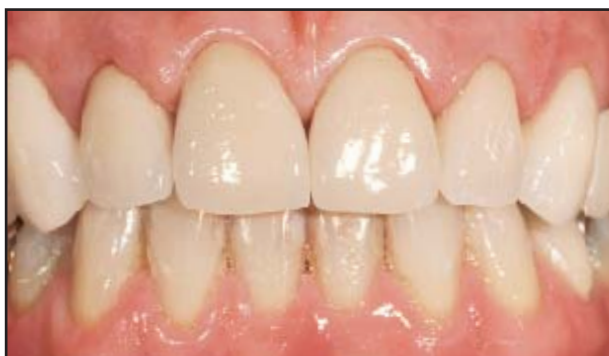**Figure 15.** Brasseler burs and diamonds are utilized throughout the “Shadow Preparation” technique.



**Figure 16.** Facial view of the completed preparations.



**Figure 17.** Available space is communicated to the laboratory with the working cast articulated with the index.



**Figure 18.** The restored dentition demonstrates aesthetics and facilitates an enhanced facial appearance.

articulated, which enabled the laboratory technician to visualize the available space between the preparations and the opposing dentition. Additionally, since the anatomic detail of the anticipated result was demonstrated in this matrix, the technician was able to identify and achieve specific aspects of the restoration, such as incisal edge length and location, angle of disclusion, and tooth position and contours.

Other materials required for laboratory fabrication of the restoration included a solid working cast and a sectioned cast. The solid cast provided the technician with essential information, such as gingival heights, scallop contours, and edentulous ridge shapes. The sectioned cast was utilized for final margination of the wax pattern. A specialty bur (H547-040, Brasseler USA, Savannah, GA) was utilized to expose the end of the dowel pins, and final die trimming was achieved with a bullet-shaped carbide cutter (H73EF-023, Brasseler USA, Savannah, GA).

**Written Prescription**—A detailed illustration of the cervical, body, and incisal aspects was included. Additionally, slides of the selected shade tabs assisted the laboratory in matching the color to the adjacent natural dentition. The age and gender of the patient were also indicated. Further, the patient was involved in shade selection to foster an interest in the restorative process and an appreciation of the clinician’s and technician’s dedication to meeting her expectations. If the opposing occlusion was to be restored or altered, the opposing cast and the prescription reflected the change. Further, translucencies, fracture lines, texture, and other anomalies were noted.

**Recorded Notations**—Utilizing a microcassette recorder, the clinician was able to describe any special circumstances or concerns specific to the restorative case. The cassette was submitted to the technician with the other materials for review prior to initiating the fabrication process. Following completion of the case, the technician returned the cassette and explained any concerns or difficulties.

## LABORATORY FABRICATION

Utilizing the materials provided by the clinician, fabrication of an accurate, durable, and functional

restoration was initiated. Each communication component provided information necessary to ensure an enhanced restoration. This process involved the waxup and framework fabrication.

**Waxup**—Utilizing appropriate models and silicone indices, the framework waxup was completed with minimal speculation.

**Framework Fabrication**—Since a bevel was utilized on the lingual aspect of the porcelain shoulder preparation, an indication mark was created on the die at the transition from shoulder to bevel. When the framework was waxed, the metal lingual band was extended to this point, ensuring that the porcelain shoulder did not extend onto the bevel. The porcelain was then under a comprehensive load and not on an angled bevel, which would have resulted in a sheer load and, eventually, porcelain fracture. The metal band was ended at this point in a 90° finish and did not taper out to a thin line, eliminating the common “fade out” of

metal, which results in an opaque or high-value look (Figure 10). After casting, the metal was finished utilizing Brasseler E-cutters (H129DF-023, H138EF-023, Brasseler USA, Savannah, GA), producing a smooth, even surface. The final surface was achieved using Brasseler diamonds (848-016, 842-018, Brasseler USA, Savannah, GA) followed by sandblasting with 50  $\mu$ m aluminum oxide. Upon completion, the framework was inspected by the laboratory technician to ensure quality and forwarded to the clinician for porcelain addition.

### Cementation and Placement

Upon return from the laboratory, the restorations were verified for accuracy of fit, occlusion, and aesthetics (Figure 11). After necessary adjustments were accomplished, a desensitizing agent (Gluma® 3, Heraeus Kulzer, Inc., South Bend, IN) was utilized, and the restorations were cemented with conventional techniques (Figure 12).

### CASE 2

A 57-year-old male patient presented with a failing, unaesthetic crown and composite restorations (Figure 13) on the anterior dentition. PFM full-coverage crown restorations were selected to fulfill the patient's functional and aesthetic expectations.

Following completion of a diagnostic waxup, the “Shadow Preparation” technique was utilized to prepare the dentition (Figures 14 and 15), facilitating adequate retention and resistance and honoring the gingival tissue (Figure 16). Provisional restorations were fabricated and approved by the patient. Impressions and indices were obtained and utilized as guides for the definitive restorations (Figure 17).

Upon completion and return to the clinician, the restorations were definitively placed (Figure 18) and incisal edge position, contours, and angle of disclusion were verified.

### CONCLUSION

The success of each restorative case is dependent upon the proper preparation protocol and comprehensive communication between the clinician, laboratory technician, and patient. The utilization of advanced rotary and diamond instruments ensures the success of the final restoration with the establishment of the “Shadow Preparation.” Communication is also key to achieving the aesthetic and functional expectations of all parties. Coordinating all the expectations and clinical concerns and utilizing the technique demonstrated in this presentation eliminates oversights and minimizes complications in the preparation, thereby enhancing the overall function, form, durability, and aesthetics of the restorative effort.

### REFERENCES

1. Dragoo MR, Williams GB. Periodontal tissue reactions to restorative procedures. *Int J Periodont Rest Dent* 1981;1(1):8-23.
2. Kois J. Altering gingival levels: The restorative connection. I. Biologic variables. *J Esthet Dent* 1994;6:3-9.
3. Shillingburg HT, Hobo S, Whitsett LD, et al. *Fundamentals of Fixed Prosthodontics*. Chicago, IL: Quintessence Publishing; 1981:79.
4. Kent WA, Shillingburg HT Jr, Duncanson MG Jr. Taper of clinical preparations for cast restorations. *Quint Int* 1988;19(5):339-345.
5. Libman WJ, Nicholls JI. Load fatigue of teeth restored with cast posts and cores and complete crowns. *Int J Prosthodont* 1995;8(2):155-161.
6. Fan P, Kois JC. Load fatigue of five restoration modalities in structurally compromised premolars. *Int J Prosthodont* 1995;8:213-220.
7. Jackson CR, Skidmore AE, Rice RT. Pulpal evaluation of teeth restored with fixed prostheses. *J Prosthet Dent* 1992;67(3):323-325.
8. Kois JC. New paradigms for anterior tooth preparation—Rationale and technique. *Contemporary Esthetic Dentistry* 1996;2(1):6-7.
9. Pascoe DF. An evaluation of the marginal adaptation of extracoronal restorations during cementation. *J Prosthet Dent* 1983;49(5):657-662.
10. Rosner D. Function, placement, and reproduction of bevels for gold castings. *J Prosthet Dent* 1963;13(6):1160-1166.
11. Ostlund LE. Cavity design and mathematics: Their effect on gaps at the margins of cast restorations. *Oper Dent* 1985;10(4):122-137.
12. Mullasseril PM. Finite element analysis of three finish lines with and without dowel cores. Oklahoma University College of Dentistry, Oklahoma City, OK; 1998. Thesis.